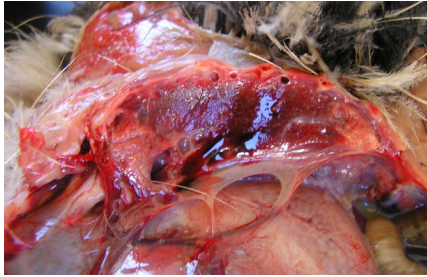



Normal lung – pink and spongy

Age: 1-day-old – adult



Diseased lung: pale pink areas show normal lung with dark red tissue indicating pneumonia

Age: All
Sporadic occurrence



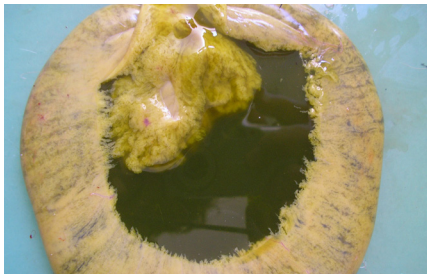
Normal windpipe – white-pink

Age: All



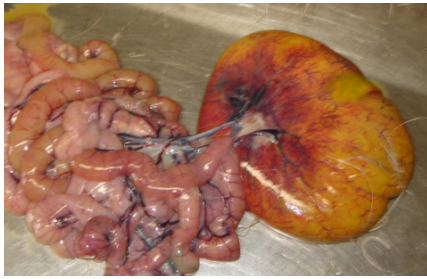
Early windpipe infection, redness and thick slime

Age: All
Moderate to frequent occurrence.
Early indication of airway disease.



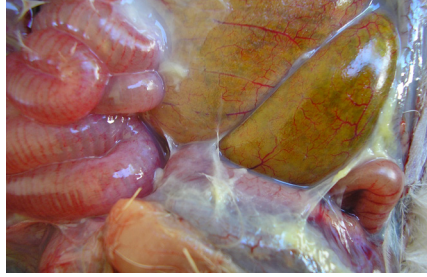Healthy yolk sac

Age: One-day-old – 14 days



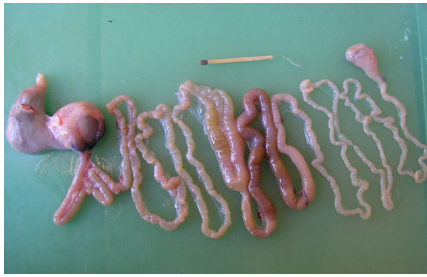Yolk sac infection:

Age: Sudden – 0-48 hours or
Chronic – 2-21 days
Seldomly occurs



Septic peritonitis – pale yellow strands between intestines

Age: Any age, but mostly in one-day-old – 48-hour-old chicks
Sporadic occurrence



Healthy Intestines of a normal one-day-old chick

Age: One to two days old




Healthy Intestines with good fill

Age: All



Poor intestinal contents and fill, poor flow-through of food and lots of gas in the intestines

Age: All
Frequent occurrence



Empty stomach of a five-day-old chick – a non starter

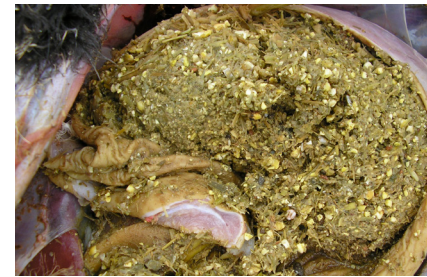Age: All
Occurrence – frequent



Far left: Bile staining with normal green colour.

Right: Bile staining of stomach due to stasis

Age: day old
Occurrence – frequent



Well-filled stomach with good contents

Age: All



Long strands of grass and fibres cause a blockage

Age: All
Occurrence – moderate to frequent



Old feed with too high fibre composition

Age: All
Occurrence – moderate to frequent



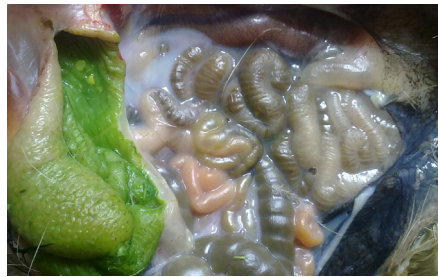

OSTRICH DISEASES

A quick guide to common diseases occurring in chicks and adult ostriches



Compiled by Dr Adriaan Olivier at Ostrimed - a division of KLEIN KAROO INTERNATIONAL PROPRIETARY LIMITED Oudtshoorn, South Africa. Tel: +27 44 203 5145 Fax: +27 44 203 5146



Normal intestines

Age: day old – 30 days



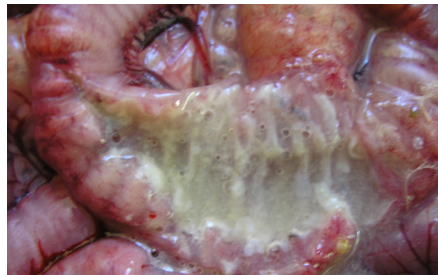Early intestine infection

Age: One-day-old to 7 days
Occurrence – sporadic to moderate. Heat stress



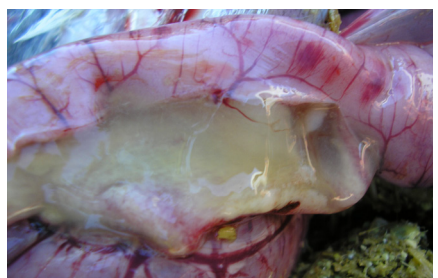Severe large intestine infections

Age: 3-14 days and 5-6 weeks
Occurrence – sporadic to moderate



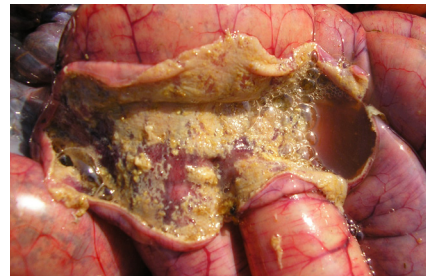Severe large intestine infection – white dead tissue

Age: 3-14 days and 5-6 weeks
Occurrence – sporadic to moderate



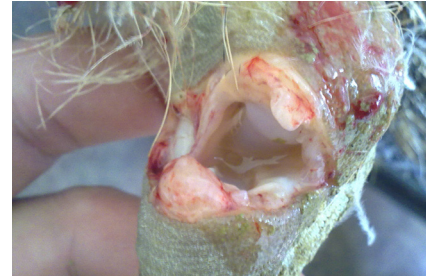Small intestine infection

Age: 4 days to 10 weeks
Occurrence – seldom



Red gut

Age: 8-20 weeks
Sporadic to moderate occurrence



Septic joint infection

Age: All
Occurrence – seldom



OSTRICH DISEASES

CONDITION	TREATMENT	RISK
Red gut	Antibiotics - dose and inject: Tetracycline	Lucerne pasture, feed changes
Large intestine infection, diarrhoea	Antibiotics - dose: Sulfonamide & Tetracycline	High energy & protein diets with stressors
Small intestine infection	Antibiotics - dose and inject: Penicillin & Macrolide	Contaminated environment
Yolk sac infection	Antibiotics - inject: Quinolone	Hygiene around time of hatching
Airway infection	Antibiotics - dose: Tetracycline For serious conditions, combine with antibiotics.	

Consult your veterinarian for the correct diagnosis and treatment strategies.